

## Section 1. Basic airway management and ventilation

### Learning outcomes

To understand:

- ▶ **The causes and recognition of airway obstruction**
- ▶ **Techniques for airway management when starting resuscitation**
- ▶ **The use of simple adjuncts to maintain airway patency**
- ▶ **The use of simple devices for ventilating the lungs**

### Introduction

Patients requiring resuscitation often have an obstructed airway, usually caused by loss of consciousness, but occasionally it may be the primary cause of cardiorespiratory arrest. Prompt assessment, with control of airway patency and provision of ventilation if required are essential. This will help to prevent secondary hypoxic damage to the brain and other vital organs. Without adequate oxygenation it may be impossible to restore an organised, perfusing cardiac rhythm. These principles may not apply to the witnessed primary cardiac arrest in the vicinity of a defibrillator; in this case, the priority is immediate defibrillation followed by attention to the airway.

### Causes of airway obstruction

Obstruction of the airway may be partial or complete. It may occur at any level from the nose and mouth down to the level of the carina and bronchi. In the unconscious patient, the commonest site of airway obstruction is the pharynx. The precise cause of airway obstruction in the unconscious state has been identified by studying patients under general anaesthesia. Airway obstruction had previously been attributed to posterior displacement of the tongue caused by decreased muscle tone, with the tongue ultimately touching the posterior pharyngeal wall. These studies of anaesthetised patients have shown that the site of airway obstruction is more often at the soft palate and epiglottis and not the tongue. Obstruction may also be caused by vomit or blood, as a result of regurgitation of gastric contents or trauma, or by foreign bodies. Laryngeal obstruction may be caused by oedema from burns, inflammation or anaphylaxis. Upper airway

stimulation or inhalation of foreign material may cause laryngeal spasm. Obstruction of the airway below the larynx is less common, but may be caused by excessive bronchial secretions, mucosal oedema, bronchospasm, pulmonary oedema, or aspiration of gastric contents. Extrinsic compression of the airway may also occur above or below the larynx e.g. trauma, haematoma or tumour.

### Recognition of airway obstruction

Airway obstruction can be subtle and is often missed by healthcare professionals. Recognition is best achieved by the look, listen and feel approach.

- LOOK for chest and abdominal movements.
- LISTEN and FEEL for airflow at the mouth and nose.

In partial airway obstruction, air entry is diminished and usually noisy.

- Inspiratory stridor - caused by obstruction at the laryngeal level or above.
- Expiratory wheeze - suggests obstruction of the lower airways, which tend to collapse and obstruct during expiration.
- Gurgling - suggests the presence of liquid or semisolid foreign material in the upper airways.
- Snoring - arises when the pharynx is partially occluded by the tongue or palate.
- Crowing or stridor - is the sound of laryngeal spasm or obstruction.

Complete airway obstruction in a patient who is making respiratory efforts causes paradoxical chest and abdominal movement, described as 'see-saw breathing'. As the patient attempts to breathe in, the chest is drawn in and the abdomen expands; the opposite occurs in expiration. This is in contrast to the normal breathing pattern of synchronous movement of the abdomen upwards and outwards (pushed down by the diaphragm) with lifting of the chest wall. During airway obstruction, accessory muscles of respiration are used - the neck and the shoulder muscles contract to assist movement of the thoracic cage. There may also be intercostal and subcostal recession and a tracheal tug. Full examination of the neck, chest and abdomen should enable differentiation of the movements associated with complete

airway obstruction from those of normal breathing. Listen for airflow: normal breathing should be quiet, completely obstructed breathing will be silent, and noisy breathing indicates partial airway obstruction.

During apnoea, when spontaneous breathing movements are absent, complete airway obstruction is recognised by failure to inflate the lungs during attempted positive pressure ventilation. Unless airway obstruction can be relieved to enable adequate lung ventilation within a few minutes it will cause injury to the brain and other vital organs, and cardiac arrest if this has not already occurred. Whenever possible, give high-concentration oxygen during the attempt to relieve airway obstruction. Arterial blood oxygen saturation (SaO<sub>2</sub>) measurements (normally using pulse oximetry [SpO<sub>2</sub>]) will guide further use of oxygen as airway patency improves. If airway patency remains poor and SaO<sub>2</sub> remains low, continue to give high inspired oxygen concentration. As airway patency improves, blood oxygen saturation levels will be restored more rapidly if the inspired oxygen concentration is initially high. Inspired oxygen concentrations can then be adjusted to maintain SaO<sub>2</sub> at 94% - 98%.

## Patients with tracheostomies or permanent tracheal stomas

A patient with a tracheostomy tube or a permanent tracheal stoma (usually following a laryngectomy) may develop airway obstruction from blockage of the tracheostomy tube or stoma — airway obstruction cannot occur at the level of the pharynx in these patients. Remove any obvious foreign material from the stoma or tracheostomy tube. If necessary, remove the tracheostomy tube or, if present, exchange the tracheostomy tube liner. If a blocked tracheostomy tube is removed it should be possible to ventilate the patient's lungs by sealing the stoma and using a bag-mask applied to the face, or by intubating the trachea orally with a standard tracheal tube. In a patient with a permanent tracheal stoma, give oxygen and, if required, assist ventilation via the stoma, and not the mouth.

## Choking

### Recognition

Foreign bodies may cause either mild or severe airway obstruction. The signs and symptoms enabling differentiation between mild and severe airway obstruction are summarised in Table 7.1.

### Sequence for the treatment of adult choking

1. If the patient shows signs of mild airway obstruction (Figure 7.1):
  - Encourage him to continue coughing, but do nothing else.

### General signs of choking

- Attack occurs while eating
- Patient may clutch his neck

#### Signs of severe airway obstruction

*Response to question 'Are you choking?'*

- Patient unable to speak
- Patient may respond by nodding

*Other signs*

- Patient unable to breathe
- Breathing sounds wheezy
- Attempts at coughing are silent
- Patient may be unconscious

#### Signs of mild airway obstruction

*Response to question 'Are you choking?'*

- Patient speaks and answers yes

*Other signs*

- Patient is able to speak, cough, and breathe

**Table 7.1 Signs of choking**

2. If the patient shows signs of severe airway obstruction and is conscious:
  - Give up to 5 back blows.
    - Stand to the side and slightly behind the patient.
    - Support the chest with one hand and lean the patient well forwards.
    - Give **up to 5** sharp blows between the scapulae with the heel of the other hand.
  - Check to see if each back blow has relieved the airway obstruction.
  - If 5 back blows fail to relieve the airway obstruction give up to 5 abdominal thrusts.
    - Stand behind the patient and put both arms round the upper part of his abdomen.
    - Place a clenched fist just under the xiphisternum; grasp this hand with your other hand and pull sharply inwards and upwards.
    - Repeat up to 5 times.
  - If the obstruction is still not relieved, continue alternating 5 back blows with 5 abdominal thrusts.
3. If the patient becomes unconscious, call the resuscitation team and start CPR.
4. As soon as an individual with appropriate skills is present, undertake laryngoscopy and attempt to remove any foreign body with Magill's forceps.

## Adult Choking Treatment Algorithm

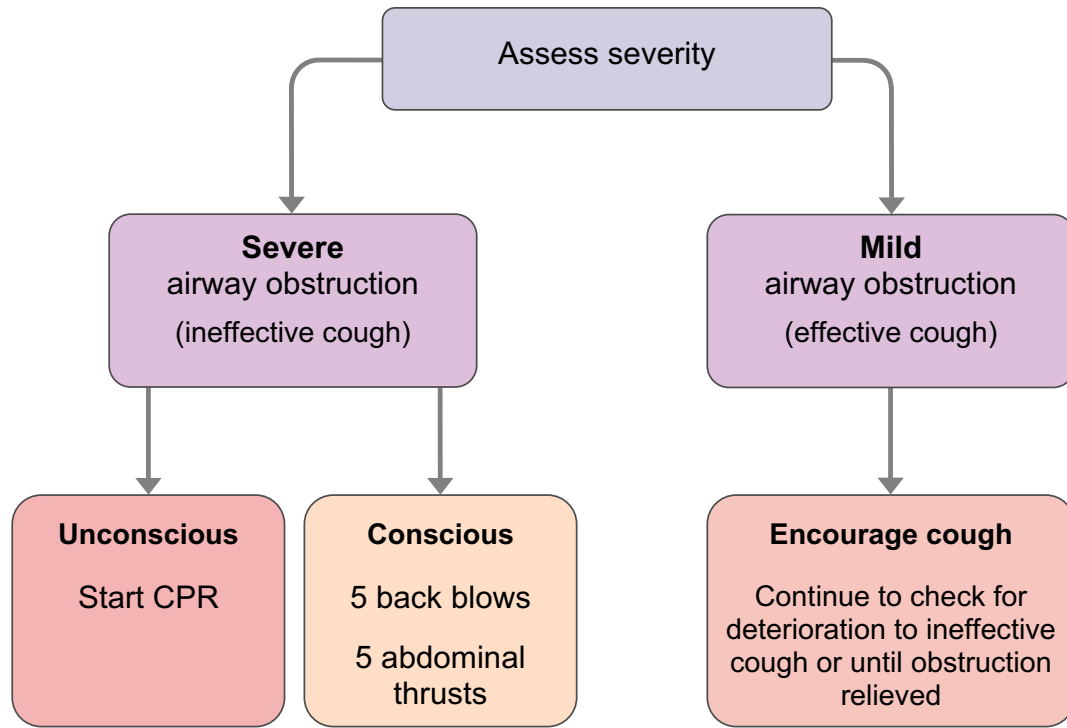


Figure 7.1 Adult choking algorithm

### Basic techniques for opening the airway

Once airway obstruction is recognised, take immediate action to relieve the obstruction and maintain a clear airway. Three manoeuvres that can be used to relieve upper airway obstruction are:

- head tilt;
- chin lift;
- jaw thrust.

#### Head tilt and chin lift

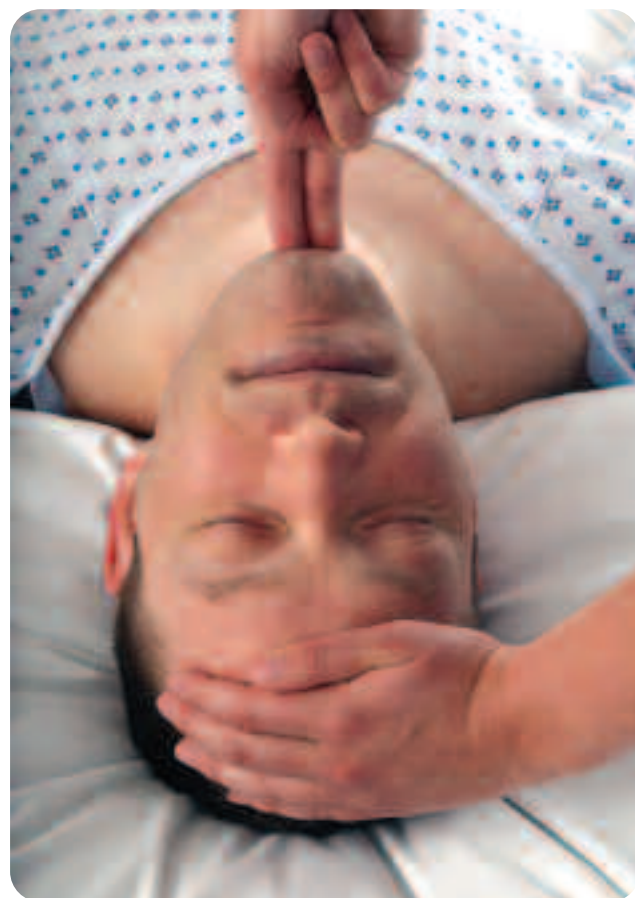
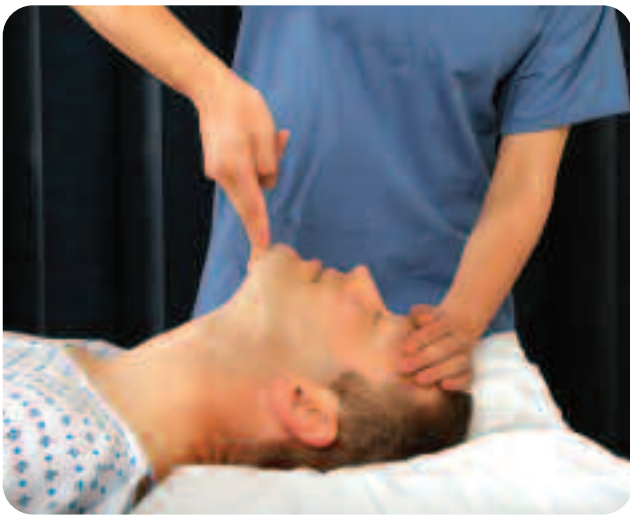Place one hand on the patient's forehead and tilt the head back gently; place the fingertips of the other hand under the point of the patient's chin, and gently lift to stretch the anterior neck structures (Figure 7.2).

#### Jaw thrust

Jaw thrust is an alternative manoeuvre for bringing the mandible forward and relieving obstruction by the tongue, soft palate and epiglottis (Figure 7.3). It is most successful when applied with a head tilt.

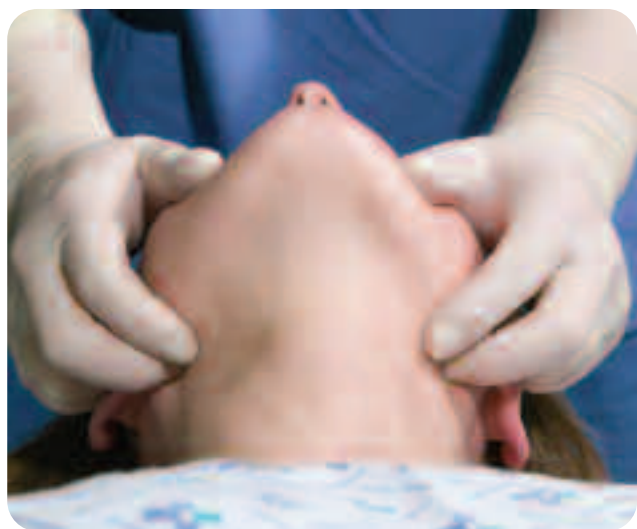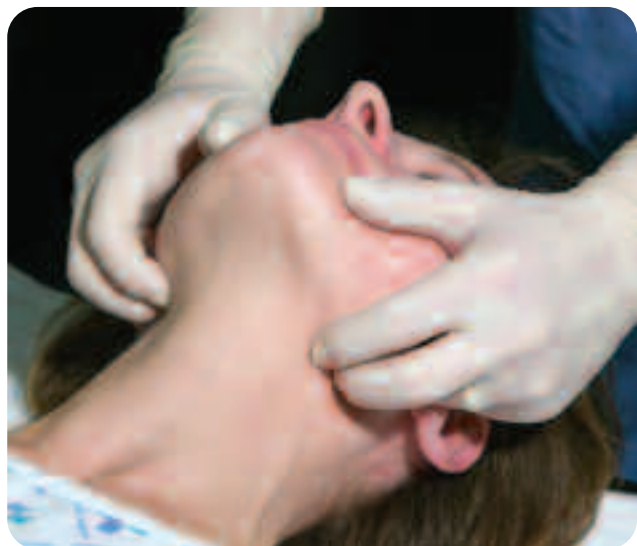#### Procedure for jaw thrust

- Identify the angle of the mandible.
- With the index and other fingers placed behind the angle of the mandible, apply steady upwards and forward pressure to lift the mandible.
- Using the thumbs, slightly open the mouth by downward displacement of the chin.



**Figure 7.2 Head tilt and chin lift**

These simple positional methods are successful in most cases where airway obstruction is caused by loss of muscle tone in the pharynx. After each manoeuvre, check for success using the look, listen and feel sequence. If a clear airway cannot be achieved, look for other causes of airway obstruction. Use a finger sweep to remove any solid foreign material visible in the mouth. Remove broken or displaced dentures but leave well-fitting dentures in place as they help to maintain the contours of the mouth, facilitating a good seal for ventilation by mouth-to-mask or bag-mask techniques.



**Figure 7.3 Jaw thrust**

### **Airway manoeuvres in a patient with suspected cervical spine injury**

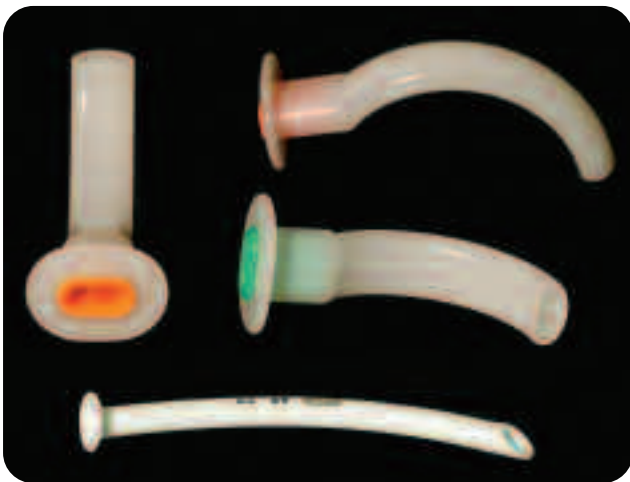
If spinal injury is suspected (e.g. if the victim has fallen, been struck on the head or neck, or has been rescued after diving into shallow water) maintain the head, neck, chest, and lumbar region in the neutral position during resuscitation. Excessive head tilt could aggravate the injury and damage the cervical spinal cord; however, this complication remains theoretical and the relative risk is unknown. When there is a risk of cervical spine injury, establish a clear upper airway by using jaw thrust or chin lift in combination with manual in-line stabilisation (MILS) of the head and neck by an assistant. If life-threatening airway obstruction persists despite effective application of jaw thrust or chin lift, add head tilt a small amount at a time until the airway is open; establishing a patent airway takes priority over concerns about a potential cervical spine injury.

## Adjuncts to basic airway techniques

Simple airway adjuncts are often helpful, and sometimes essential to maintain an open airway, particularly when resuscitation is prolonged. The position of the head and neck must be maintained to keep the airway aligned. Oropharyngeal and nasopharyngeal airways are designed to overcome soft palate obstruction and backward tongue displacement in an unconscious patient, but head tilt and jaw thrust may also be required.

### Oropharyngeal airway

The oropharyngeal or Guedel airway is a curved plastic tube, flanged and reinforced at the oral end with a flattened shape to ensure that it fits neatly between the tongue and hard palate (Figure 7.4). It is available in sizes suitable for small and large adults. An estimate of the size required may be obtained by selecting an airway with a length corresponding to the vertical distance between the patient's incisors and the angle of the jaw (Figure 7.5). The most common sizes are 2, 3 and 4 for small, medium and large adults respectively. An oropharyngeal airway that is slightly too big will be more beneficial than one that is slightly too small.

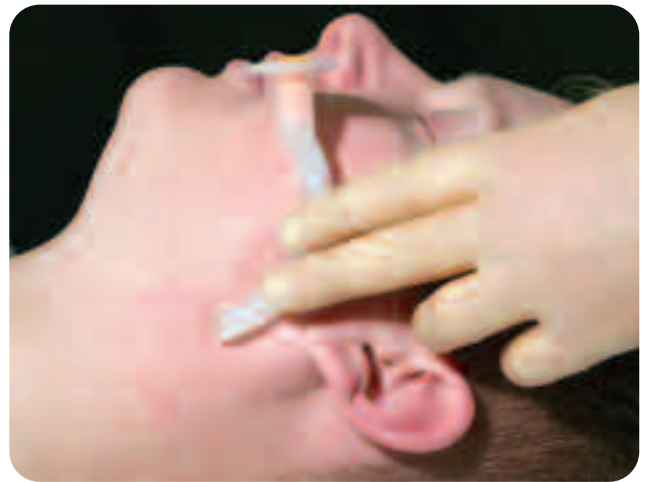

**Figure 7.4 Oropharyngeal and nasopharyngeal airways**

During insertion of an oropharyngeal airway, the tongue can occasionally be pushed backwards, exacerbating obstruction instead of relieving it. The oropharyngeal airway may lodge in the vallecula, or the epiglottis may obstruct the lumen. Ensuring a correct insertion technique should avoid this problem. Attempt insertion only in unconscious patients: vomiting or laryngospasm may occur if glossopharyngeal or laryngeal reflexes are present.

### Technique for insertion of an oropharyngeal airway:

- Open the patient's mouth and ensure that there is no foreign material that may be pushed into the larynx (if there is any, then use suction to remove it).



**Figure 7.5 Sizing an oropharyngeal airway**

- Insert the airway into the oral cavity in the 'upside-down' position as far as the junction between the hard and soft palate and then rotate it through 180° (Figure 7.6). Advance the airway until it lies within the pharynx. This rotation technique minimises the chance of pushing the tongue backwards and downwards. Remove the airway if the patient gags or strains. Correct placement is indicated by an improvement in airway patency and by the seating of the flattened reinforced section between the patient's teeth or gums (if edentulous). A jaw thrust may further aid final placement of the airway as it is finally pushed into the correct position

After insertion, maintain head-tilt/chin-lift or jaw thrust, and check the patency of the airway and ventilation using the look, listen and feel technique. Where there is suspicion of an injury to the cervical spine, maintain alignment and immobilisation of the head and neck. Suction is usually possible through an oropharyngeal airway using a fine bore flexible suction catheter.

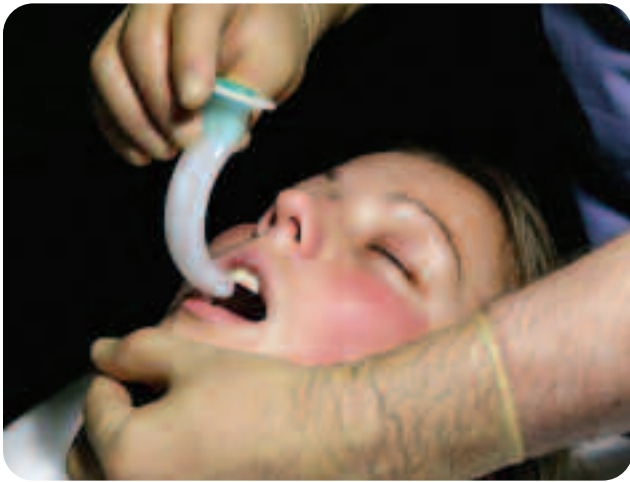

Figure 7.6 Oral airway insertion

## Nasopharyngeal airway

This is made from soft malleable plastic, bevelled at one end and with a flange at the other (Figure 7.4). In patients who are not deeply unconscious, it is tolerated better than an oropharyngeal airway. It may be life-saving in patients with clenched jaws, trismus or maxillofacial injuries.

Inadvertent insertion of a nasopharyngeal airway through a fracture of the skull base and into the cranial vault is possible, but extremely rare. In the presence of a known or suspected basal skull fracture an oral airway is preferred, but if this is not possible, and the airway is obstructed, gentle insertion of a nasopharyngeal airway may be life-saving (i.e. the benefits may far outweigh the risks).

The tubes are sized in millimetres according to their internal diameter, and the length increases with diameter. The traditional methods of sizing a nasopharyngeal airway (measurement against the patient's little finger or anterior nares) do not correlate with the airway anatomy and are unreliable. Sizes 6 - 7 mm are suitable for adults. Insertion can cause damage to the mucosal lining of the nasal airway, resulting in bleeding in up to 30% of cases. If the tube is too long it may stimulate the laryngeal or glossopharyngeal reflexes to produce laryngospasm or vomiting.

### Technique for insertion of a nasopharyngeal airway

- Check for patency of the right nostril.
- Some designs require a safety pin to be inserted through the flange to provide an extra precaution against the airway disappearing beyond the nares. The safety pin should be inserted BEFORE inserting the airway.
- Lubricate the airway thoroughly using water-soluble jelly.

- Insert the airway bevel end first, vertically along the floor of the nose with a slight twisting action (Figure 7.7). The curve of the airway should direct it towards the patient's feet. If any obstruction is met, remove the tube and try the left nostril.
- Once in place, use the look, listen and feel technique to check the patency of the airway and adequacy of ventilation. Chin lift or jaw thrust may still be required to maintain airway patency. Where there is suspicion of an injury to the cervical spine, maintain correct alignment and immobilisation of the head and neck.

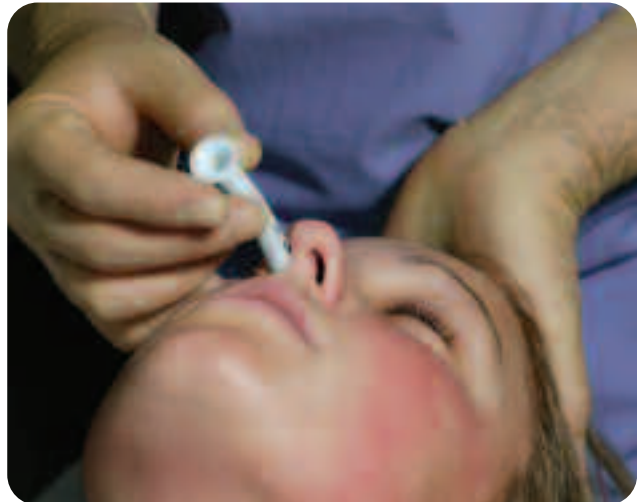

Figure 7.7 Nasal airway insertion

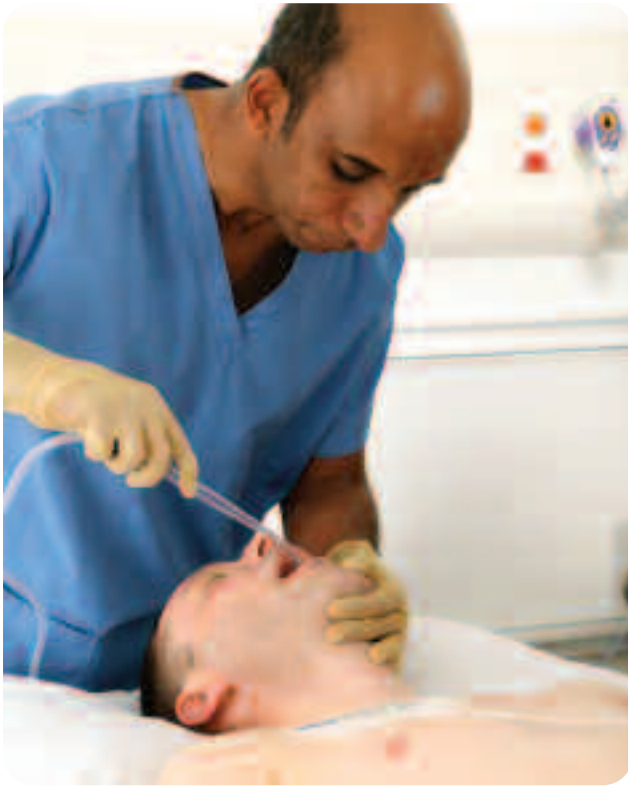## Oxygen

In the absence of data indicating the optimal  $\text{SaO}_2$  during CPR, ventilate the lungs with 100% until return of spontaneous circulation (ROSC) is achieved. After ROSC is achieved and in any acutely ill, or unconscious patient, give high-flow oxygen until the  $\text{SaO}_2$  can be measured reliably. There are some registry data indicating an association between hyperoxaemia after ROSC and worse outcome. A standard oxygen mask will deliver up to 50%, providing the flow of oxygen is high enough. Initially, give the highest possible oxygen concentration - a mask with reservoir bag (non-rebreathing mask) can deliver an inspired oxygen concentration of 85% at flow rates of  $10 \text{ l min}^{-1}$ . Monitor the  $\text{SpO}_2$  or arterial blood gases to enable titration of the inspired oxygen concentration. When blood oxygen saturation can be measured reliably,  $\text{SpO}_2$  should be maintained at 94% - 98%; or 88% - 92% if the patient has COPD.

## Suction

Use a wide-bore rigid sucker (Yankauer) to remove liquid (blood, saliva and gastric contents) from the upper airway (Figure 7.8). Use the sucker cautiously if the patient has an

intact gag reflex – it can provoke vomiting. Fine-bore flexible suction catheters may be required in patients with limited mouth opening. These suction catheters can also be passed through oropharyngeal or nasopharyngeal airways.



**Figure 7.8 Suctioning**

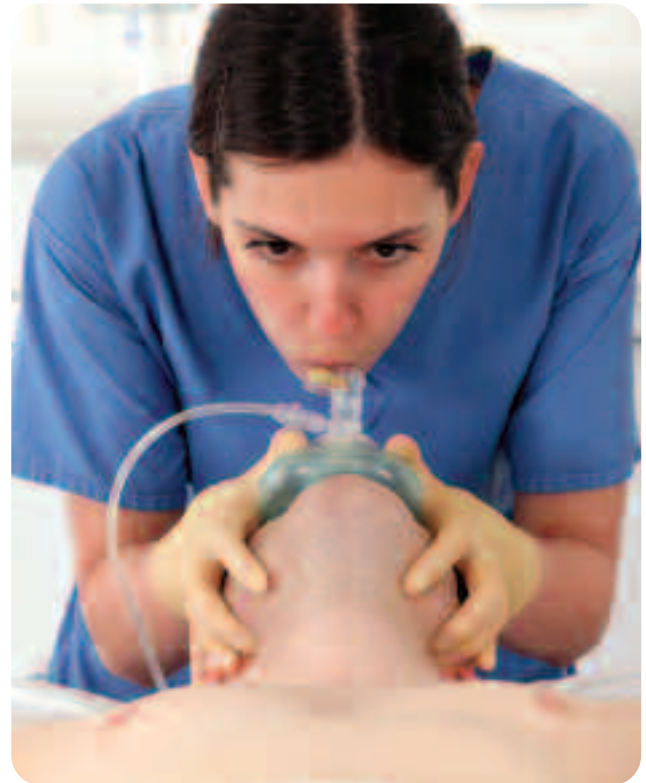## Ventilation

Artificial ventilation is started as soon as possible in any patient in whom spontaneous ventilation is inadequate or absent. Expired air ventilation (rescue breathing) is effective but the rescuer's expired oxygen concentration is only 16 - 17%; so it must be replaced as soon as possible by ventilation with oxygen-enriched air. Although mouth-to-mouth ventilation has the benefit of not requiring any equipment, the technique is aesthetically unpleasant, particularly when vomit or blood is present, and the rescuer may be reluctant to place themselves in intimate contact with the victim who may be unknown to them.

There are only isolated reports of individuals acquiring infections after providing CPR, e.g. tuberculosis and severe acute respiratory distress syndrome (SARS). Transmission of HIV during provision of CPR has never been reported. Simple adjuncts are available to enable direct person-to-person contact to be avoided; some of these devices may reduce the risk of cross infection between patient and rescuer.

The pocket resuscitation mask is used widely. It is similar to an anaesthetic face mask and enables mouth-to-mask

ventilation. It has a unidirectional valve, which directs the patient's expired air away from the rescuer. The mask is transparent so that vomit or blood from the patient can be seen. Some masks have a port for the addition of oxygen. When using masks without an oxygen port, supplemental oxygen can be given by placing oxygen tubing underneath one side and ensuring an adequate seal. Use a two-hand technique to maximise the seal with the patient's face (Figure 7.9).



**Figure 7.9 Mouth-to-mask ventilation**

High airway pressures can be generated if the tidal volumes or inspiratory flows are too great, predisposing to gastric inflation and subsequent risk of regurgitation and pulmonary aspiration. As gastric inflation occurs, lung compliance is further reduced making ventilation more difficult. The possibility of gastric inflation is increased by:

- malalignment of the head and neck, and an obstructed airway;
- an incompetent oesophageal sphincter (present in all patients with cardiac arrest);
- a high inflation pressure.

Tidal volumes in the region of 6 - 7 ml kg<sup>-1</sup> will provide adequate oxygenation and ventilation, and will reduce the risk of gastric inflation. If inspiratory flow is too low, inspiratory time will be prolonged and the time available to give chest compressions is reduced. Deliver each breath over approximately 1 s and give a volume that

corresponds to normal visible chest movement; this represents a compromise between giving an adequate volume, minimising the risk of gastric inflation, and allowing adequate time for chest compressions. During CPR with an unprotected airway, give 2 ventilations after each sequence of 30 chest compressions.

### Technique for mouth-to-mask ventilation

- Place the patient supine with the head in a 'sniffing' position i.e. neck slightly flexed on a pillow with the head extended (tilted backwards) on the neck.
- Apply the mask to the patient's face using the thumbs of both hands.
- Lift the jaw into the mask with the remaining fingers by exerting pressure behind the angles of the jaw (jaw thrust). At the same time, press the mask onto the face with the thumbs to make a tight seal (Figure 7.9).
- Blow gently through the inspiratory valve and watch the chest rise normally.
- Stop inflation and observe the chest falling.
- Any leaks between the face and mask can be reduced by adjusting the contact pressure, altering the position of the fingers and thumbs, or increasing jaw thrust.
- If oxygen is available, add it via the port at a flow of 10 l min<sup>-1</sup>.

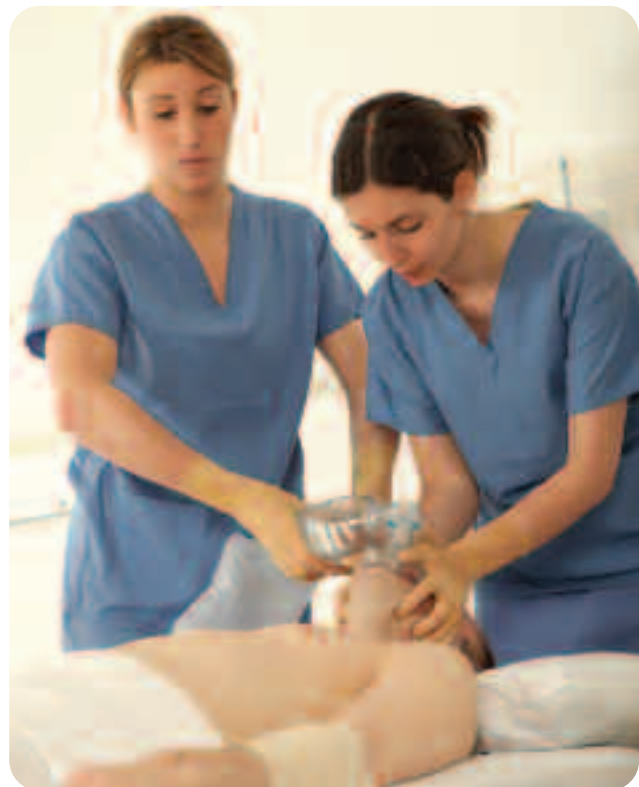### Self-inflating bag

The self-inflating bag can be connected to a face mask, tracheal tube, or supraglottic airway device. As the bag is squeezed, the contents are delivered to the patient's lungs. On release, the expired gas is diverted to the atmosphere via a one-way valve; the bag then refills automatically via an inlet at the opposite end. When used without supplemental oxygen, the self-inflating bag ventilates the patient's lungs with only ambient air (oxygen concentration 21%). This is increased to around 45% by attaching high-flow oxygen directly to the bag adjacent to the air intake. An inspired oxygen concentration of approximately 85% is achieved if a reservoir system is attached and the oxygen flow is maximally increased. As the bag re-expands it fills with oxygen from both the reservoir and the continuous flow from the attached oxygen tubing.

Although the bag-mask apparatus enables ventilation with high concentrations of oxygen, its use by a single person requires considerable skill. When used with a face mask, it is often difficult to achieve a gas-tight seal between the mask and the patient's face, and maintain a patent airway with one hand whilst squeezing the bag with the other. Any significant leak will cause hypoventilation and if the airway

is not patent, gas may also be forced into the stomach. This will reduce ventilation further and greatly increase the risk of regurgitation and aspiration. There is a natural tendency to try to compensate for a leak by excessive compression of the bag, which causes high peak airway pressures and forces more gas into the stomach. Some self-inflating bags have flow restrictors that limit peak airway pressure with the aim of reducing gastric inflation. Cricoid pressure can reduce the risk of gastric inflation but requires the presence of a trained assistant. Poorly applied cricoid pressure may make it more difficult to ventilate the patient's lungs.

The two-person technique for bag-mask ventilation is preferable (Figure 7.10). One person holds the face mask in place using a jaw thrust with both hands and an assistant squeezes the bag. In this way, a better seal can be achieved and the patient's lungs can be ventilated more effectively and safely.



**Figure 7.10 The two-person technique for bag-mask ventilation**

### Key learning points

- Airway patency and ventilating the lungs are important components of CPR.
- Use of simple airway manoeuvres, with or without basic adjuncts, will often achieve a patent airway.
- Give all patients high-concentration oxygen until the arterial oxygen saturation is measurable.

## Section 2. Alternative airway devices

### Learning outcomes

To understand:

- ▶ **The role of supraglottic airway devices during CPR**

### Introduction

Effective bag-mask ventilation requires a reasonable level of skill and experience: the inexperienced are likely to achieve ineffective tidal volumes and cause gastric inflation with risk of regurgitation and pulmonary aspiration. In comparison with bag-mask ventilation, use of supraglottic airway devices (SADs) may enable more effective ventilation and reduce the risk of gastric inflation. Furthermore, SADs are easier to insert than a tracheal tube and, unlike tracheal intubation, they can generally be positioned without interrupting chest compressions.

Without adequate training and experience, the incidence of complications associated with attempted tracheal intubation is unacceptably high. Unrecognised oesophageal intubation is disastrous and prolonged attempts at tracheal intubation are harmful: the pause in chest compressions during this time will severely compromise coronary and cerebral perfusion. Alternative airway devices should be used if attempted tracheal intubation by those highly skilled to perform the technique has failed or by all other personnel not skilled in regular intubation of the trachea.

There are no data supporting the routine use of any specific approach to airway management during cardiac arrest. The best technique is dependent on the precise circumstances of the cardiac arrest and the competence of the rescuer.

### Laryngeal mask airway

The laryngeal mask airway (LMA) consists of a wide-bore tube with an elliptical inflated cuff designed to seal around the laryngeal opening (Figure 7.11). It was introduced into anaesthetic practice in the middle of the 1980s and is a reliable and safe device, which can be introduced easily, with a high success rate after a short period of training. Ventilation using the LMA is more efficient and easier than with a bag-mask apparatus; provided high inflation pressures ( $>20$  cmH<sub>2</sub>O) are avoided, gastric inflation is minimised. When an LMA can be inserted without delay it is preferable to avoid bag-mask ventilation altogether: the risk of gastric inflation and regurgitation is reduced. Though not guaranteeing protection of the airway from gastric contents, pulmonary aspiration during use of the LMA is uncommon. The LMA does protect against sources

of aspiration from above the larynx. Use of the LMA by nursing, paramedical and medical staff during resuscitation has been studied and reported to be effective. Like tracheal intubation, it requires the patient to be deeply unconscious. The LMA is particularly valuable if attempted intubation by skilled personnel has failed and bag-mask ventilation is impossible (the cannot ventilate, cannot intubate scenario). The conventional LMA (LMA Classic™) can be reused up to 40 times after sterilisation. The practical limitations imposed by having to resterilise the LMA Classic™ make the single-use versions of the LMA more suitable for prehospital use and for cardiac arrests in hospital. However, some of the single-use LMAs are of a slightly different design and material to the LMA Classic™ and their performance has not been validated in the CPR setting.

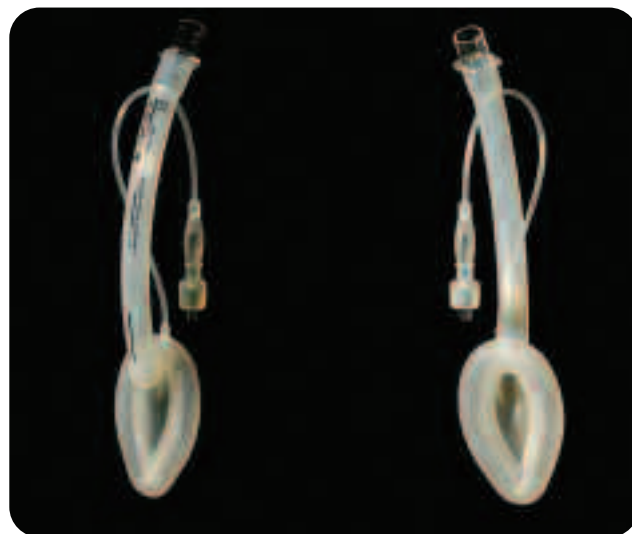

Figure 7.11 Laryngeal mask airway

### Technique for insertion of a laryngeal mask airway

- Try to maintain chest compressions throughout the insertion attempt; if it is necessary to stop chest compressions during the insertion attempt, limit this pause in chest compressions to a maximum of 10 s.
- Select a LMA of an appropriate size for the patient and deflate the cuff fully. A size 5 will be correct for most men and a size 4 for most women. Lubricate the outer face of the cuff area (the part that will not be in contact with the larynx) with water-soluble gel.
- Flex the patient's neck slightly and extend the head (try to maintain neutral alignment of the head and neck if there is suspicion of cervical spine injury).
- Holding the LMA like a pen, insert it into the mouth (Figure 7.12). Advance the tip behind the upper incisors with the upper surface applied to the palate until it reaches the posterior pharyngeal wall. Press the mask backwards and downwards around the

corner of the pharynx until a resistance is felt as it locates in the back of the pharynx. If possible, get an assistant to apply a jaw thrust after the LMA has been inserted into the mouth - this increases the space in the posterior pharynx and makes successful placement easier. A slight 45 degree twist will often aid placement if initial attempts at insertion beyond the pharynx are proving difficult.

- Connect the inflating syringe and inflate the cuff with air (40 ml for a size 5 LMA and 30 ml for a size 4 LMA); alternatively, inflate the cuff to a pressure of 60 cmH<sub>2</sub>O. If insertion is satisfactory, the tube will lift 1 - 2 cm out of the mouth as the cuff finds its correct position and the larynx is pushed forward.
- If the LMA has not been inserted successfully after 30 s, oxygenate the patient using a pocket mask or bag-mask before reattempting LMA insertion.
- Confirm a clear airway by listening over the chest during inflation and observing bilateral chest movement. A large, audible leak suggests malposition of the LMA, but a small leak is acceptable provided chest rise is adequate.
- Insert a bite block alongside the tube if available and secure the LMA with a bandage or tape.

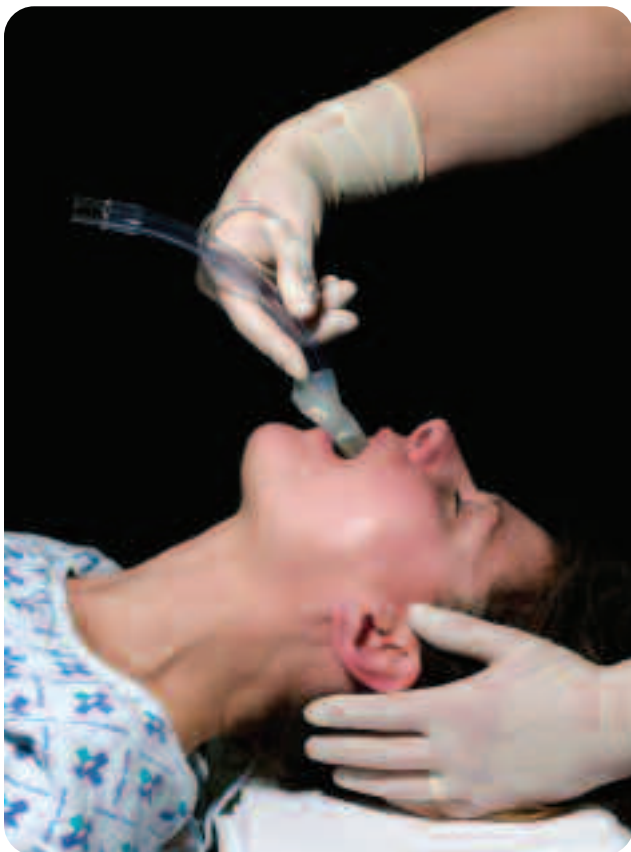

Figure 7.12 Insertion of a laryngeal mask airway

## Limitations of the LMA

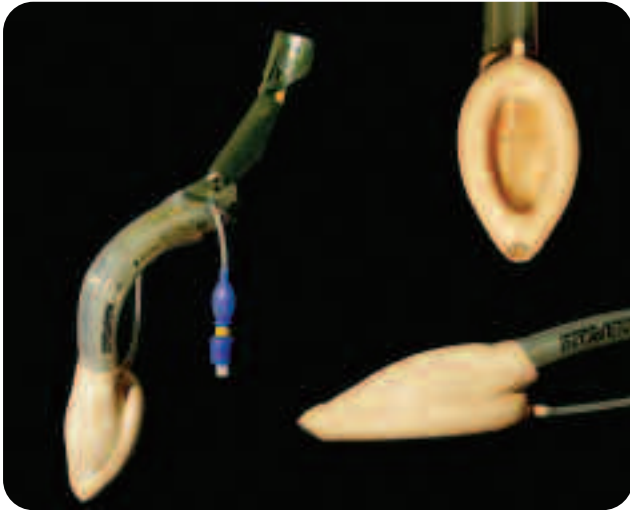- In the presence of high airway resistance or poor lung compliance (pulmonary oedema, bronchospasm, chronic obstructive pulmonary disease) there is a risk of a significant leak around the cuff causing hypoventilation. Most of the gas leaking around the cuff normally escapes through the patient's mouth but some gastric inflation may occur.
- There are no data demonstrating whether or not it is possible to provide adequate ventilation via an LMA without interruption of chest compressions. Uninterrupted chest compressions are likely to cause at least some gas leak from the LMA cuff when ventilation is attempted. Attempt continuous compressions initially but abandon this if persistent leaks and hypoventilation occur.
- There is a theoretical risk of aspiration of stomach contents because the LMA does not sit within the larynx like a tracheal tube; however, this complication has not been documented widely in clinical practice.
- If the patient is not deeply unconscious, insertion of the LMA may cause coughing, straining or laryngeal spasm. This will not occur in patients in cardiorespiratory arrest.
- If an adequate airway is not achieved, withdraw the LMA, deflate the cuff and attempt reinsertion ensuring a good alignment of the head and neck.
- Uncommonly, airway obstruction may be caused by the epiglottis folding down to cover the laryngeal inlet. Withdraw the LMA, deflate the cuff and attempt reinsertion.

To become proficient in the insertion of an LMA requires practice on patients and this should be achieved under the supervision of an appropriately experienced person (e.g. anaesthetist) in a controlled environment.

## The ProSeal LMA

The ProSeal LMA (PLMA) is a modified version of the original LMA. It has an additional posterior cuff and a gastric drain tube (Figure 7.13). The device has been studied extensively in anaesthetised patients, but there are no studies of its function and performance during CPR. It has several attributes that, in theory, make it more suitable than the original LMA for use during CPR: improved seal with the larynx enabling ventilation at higher airway pressures (commonly up to 35 - 40 cmH<sub>2</sub>O), the inclusion of a gastric drain tube enabling venting of liquid regurgitated gastric contents from the upper oesophagus and passage of a gastric tube to drain liquid gastric contents, and the inclusion of a bite block. The higher seal pressures achieved with the PLMA may enable ventilation volume to be maintained during uninterrupted chest compressions.

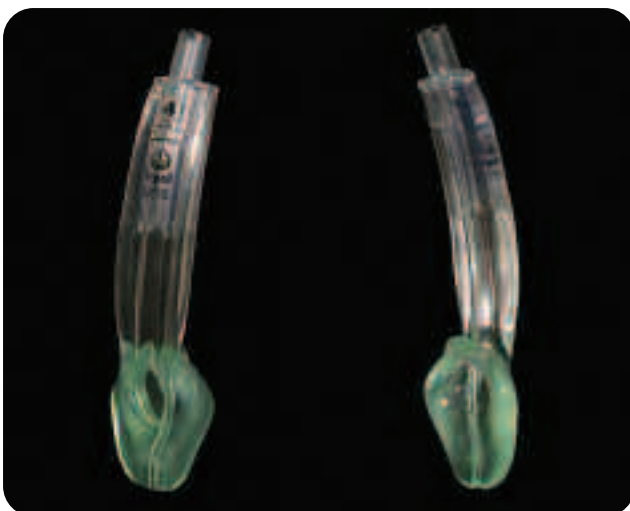Potential weaknesses of the PLMA as an airway device for CPR are that it is slightly more difficult to insert than the original LMA, it is relatively expensive and that solid, regurgitated gastric contents could block the gastric drain tube. Recently a disposable form of the PLMA has become available - the LMA Supreme. It has a more rigid shape and lacks a posterior inflatable cuff. Apart from two case reports, there are few data on the use of this device in CPR at present.



**Figure 7.13** Proseal LMA

### i-gel airway

The i-gel is a relatively new supraglottic airway. The cuff is made of thermoplastic elastomer gel and does not require inflation; the stem of the i-gel incorporates a bite block and a narrow oesophageal drain tube (Figure 7.14). It is easy to insert, requiring only minimal training and a laryngeal seal pressure of 20 - 24 cmH<sub>2</sub>O can be achieved. In two manikin studies, insertion of the i-gel was significantly faster than several other airway devices. The ease of insertion of the i-gel and its favourable leak pressure make it theoretically very attractive as a resuscitation airway device for those inexperienced in tracheal intubation. Use

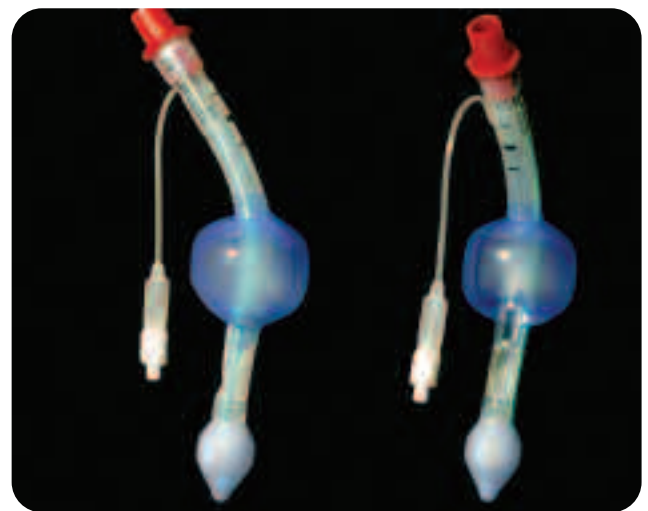

**Figure 7.14** i-gel

of the i-gel during cardiac arrest has been reported but more data on its use in this setting are awaited.

### Laryngeal tube

The laryngeal tube (LT) is another of the new supraglottic airway devices that have been developed. It is a single-lumen tube with both an oesophageal and pharyngeal cuff (Figure 7.15). A single pilot balloon inflates both cuffs simultaneously and it is available in a variety of sizes. Successful insertion and airway pressures generated are comparable to the LMA when performed by non-anaesthetists. There are several observational studies that document successful use of the LT by nurses and paramedics during prehospital cardiac arrest. A double lumen LT with an oesophageal vent and a disposable version (LT-D) are available.



**Figure 7.15** Laryngeal tube

### Key learning points

- Supraglottic airway devices are good alternatives to the bag-mask and should be used instead of the bag-mask technique wherever possible.
- Supraglottic airway devices should be used instead of tracheal intubation unless individuals highly skilled in intubation are immediately available. They should also be used if attempted intubation is unsuccessful.

## Section 3. Tracheal intubation and cricothyroidotomy

### Learning outcomes

To understand:

- ▶ **The advantages and disadvantages of tracheal intubation during cardiopulmonary resuscitation**
- ▶ **Some simple aids to tracheal intubation**
- ▶ **Some methods for confirming correct placement of a tracheal tube**
- ▶ **The role of needle and surgical cricothyroidotomy**

### Tracheal intubation

There is insufficient evidence to support or refute the use of any specific technique to maintain an airway and provide ventilation in adults with cardiorespiratory arrest. Despite this, tracheal intubation is perceived as the optimal method of providing and maintaining a clear and secure airway. It should be used only when trained personnel are available to carry out the procedure with a high level of skill and competence. A systematic review of randomised controlled trials (RCTs) of tracheal intubation versus alternative airway management in acutely ill and injured patients has identified just three trials: two were RCTs of the Combitube versus tracheal intubation for out-of-hospital cardiac arrest which showed no difference in survival. The third study was a RCT of prehospital tracheal intubation versus management of the airway with a bag-mask in children requiring airway management for cardiac arrest, primary respiratory disorders and severe injuries. There was no overall benefit for tracheal intubation; on the contrary, of the children requiring airway management for a respiratory problem, those randomised to intubation had a lower survival rate than those in the bag-mask group. The Ontario Prehospital Advanced Life Support (OPALS) study has also documented no increase in survival to hospital discharge when the skills of tracheal intubation and injection of cardiac supporting drugs were added to an optimised basic life support-automated external defibrillator system.

The perceived advantages of tracheal intubation over bag-mask ventilation include maintenance of a patent airway which is protected from aspiration of gastric contents or blood from the oropharynx, ability to provide an adequate tidal volume reliably even when chest compressions are uninterrupted, the potential to free the rescuers hands for other tasks and the ability to suck-out airway secretions. Use of a bag-mask is more likely to cause gastric distension, which, theoretically, is more likely to cause

regurgitation and the risk of aspiration. This theoretical risk has yet to be proven in randomised clinical trials.

The perceived disadvantages of tracheal intubation over bag-mask ventilation include the risk of an unrecognised misplaced tracheal tube (which is as high as 17% in some studies of out-of-hospital cardiac arrest), a prolonged time without chest compressions while tracheal intubation is attempted (tracheal intubation attempts accounted for almost 25% of all CPR interruptions in one prehospital study) and a comparatively high failure rate. Tracheal intubation success rates correlate with the intubation experience attained by the rescuer. Rates for failure to intubate the trachea are as high as 50% in prehospital systems with a low patient volume and providers who do not perform intubation frequently. The cost of training prehospital staff to undertake tracheal intubation should also be considered. Healthcare personnel who undertake prehospital intubation should do so only within a structured, monitored program, which should include comprehensive competency-based training and regular opportunities to refresh skills.

Rescuers must therefore weigh the risks and benefits of tracheal intubation against the need to provide effective chest compressions. The intubation attempt will require some interruption of chest compressions but, once an advanced airway is in place, ventilation will not require further interruption of chest compressions. Personnel skilled in advanced airway management should be able to undertake laryngoscopy without stopping chest compressions; a brief pause in chest compressions will be required only as the tube is passed through the vocal cords. Alternatively, to avoid any interruptions in chest compressions, the intubation attempt may be deferred until ROSC. No tracheal intubation attempt should interrupt chest compressions for more than 10 s; if intubation is not achievable within these constraints, recommence bag-mask or bag-supraglottic airway device ventilation. After tracheal intubation, tube placement must be confirmed and the tube secured adequately. If there is any doubt about the correct position of the tube, remove it and re-oxygenate the patient before making another attempt.

In some cases, laryngoscopy and attempted intubation may prove impossible or cause life-threatening deterioration in the patient's condition. Such circumstances include acute epiglottitis, pharyngeal pathology, head injury (where coughing or straining may cause further increase in intracranial pressure), or in patients with cervical spine injury. In these circumstances, specialist skills such as the use of anaesthetic drugs or flexible fiberoptic laryngoscopy may be required. Such techniques require a high level of skill and training.

## Essential equipment for tracheal intubation

- Laryngoscope - generally a curved Macintosh blade. Several sizes are available, but a size 3 will be adequate for most patients. Check the light source and battery regularly and just before use, and ensure that spares are immediately available.
- Cuffed tracheal tubes - a selection should be available appropriate to the size of the patient. An 8 mm internal diameter tube is suitable for an adult male and a 7 mm internal diameter tube for a female.
- Sizes 6, 7 and 8 mm will generally cover the immediate needs of all adults. Availability of smaller tracheal tubes will be helpful for patients with conditions causing narrowing of the upper airway.
- Syringe for cuff inflation.
- Equipment for confirming correct placement of the tracheal tube.
- Extras:
  - water-soluble lubricating jelly;
  - Magill's forceps;
  - introducers: either a gum elastic bougie or a semi-rigid stylet;
  - tape or bandage to secure tube in position;
  - suction apparatus with a wide-bore rigid suction end (e.g. Yankauer) and a range of smaller flexible catheters.

## Post-intubation procedures

- After successful intubation, connect the tracheal tube (via a catheter mount if necessary) to a ventilating device, e.g. self-inflating bag, and ventilate with the highest oxygen concentration available.
- Inflate the cuff of the tracheal tube just sufficiently to stop an air leak during inspiration.
- Confirm correct placement of the tracheal tube using clinical assessment AND a technique for secondary confirmation - waveform capnography is the most reliable secondary technique (see below).
- Continue ventilation with a high concentration of oxygen until ROSC and oxygen saturations are recordable.
- Secure the tube with a bandage or tie. Adhesive tape is not reliable if the face is moist.

- An oropharyngeal airway may be inserted alongside the tracheal tube to maintain the position of the tube, and prevent damage from biting when consciousness returns.

## Confirmation of correct tracheal tube placement

Unrecognised oesophageal intubation is the most serious complication of attempted tracheal intubation. Routine use of primary and secondary techniques to confirm correct placement of the tracheal tube will reduce this risk.

### Clinical assessment

Primary assessment includes observation of chest expansion bilaterally, auscultation over the lung fields bilaterally in the axillae (breath sounds should be equal and adequate) and over the epigastrium (breath sounds should not be heard). Clinical signs of correct tube placement (condensation in the tube, chest rise, breath sounds on auscultation of lungs, and inability to hear gas entering the stomach) are not completely reliable. The reported sensitivity (proportion of tracheal intubations correctly identified) and specificity (proportion of oesophageal intubations correctly identified) of clinical assessment varies.

Secondary confirmation of tracheal tube placement by an exhaled carbon dioxide or oesophageal detection device should reduce the risk of unrecognised oesophageal intubation but the performance of the available devices varies considerably. Furthermore, none of the secondary confirmation techniques will differentiate between a tube placed in a main bronchus and one placed correctly in the trachea.

### Oesophageal detector device

The oesophageal detector device creates a suction force at the tracheal end of the tracheal tube, either by pulling back the plunger on a large syringe or releasing a compressed flexible bulb. Air is aspirated easily from the lower airways through a tracheal tube placed in the cartilage-supported rigid trachea. When the tube is in the oesophagus, air cannot be aspirated because the oesophagus collapses when aspiration is attempted. The oesophageal detector device may be misleading in patients with morbid obesity, late pregnancy or severe asthma or when there are copious tracheal secretions; in these conditions the trachea may collapse when aspiration is attempted.

### Carbon dioxide detectors

Carbon dioxide (CO<sub>2</sub>) detector devices measure the concentration of exhaled carbon dioxide from the lungs. The persistence of exhaled CO<sub>2</sub> after six ventilations indicates placement of the tracheal tube in the trachea or a main bronchus. Confirmation of correct placement

above the carina will require auscultation of the chest bilaterally in the mid-axillary lines. Broadly, there are three types of carbon dioxide detector device:

1. Disposable colorimetric end-tidal carbon dioxide (ETCO<sub>2</sub>) detectors use a litmus paper to detect CO<sub>2</sub>, and these devices generally give readings of purple (ETCO<sub>2</sub> <0.5%), tan (ETCO<sub>2</sub> 0.5 - 2%) and yellow (ETCO<sub>2</sub> > 2%). In most studies, tracheal placement of the tube is considered verified if the tan colour persists after a few ventilations. Although colorimetric CO<sub>2</sub> detectors identify placement quite well in patients with good perfusion, these devices are less accurate than clinical assessment in cardiac arrest patients because pulmonary blood flow may be so low that there is insufficient exhaled carbon dioxide. Furthermore, if the tracheal tube is in the oesophagus, six ventilations may lead to gastric distension, vomiting and aspiration.
2. Non-waveform electronic digital ETCO<sub>2</sub> devices generally measure ETCO<sub>2</sub> using an infrared spectrometer and display the results with a number; they do not provide a waveform graphical display of the respiratory cycle on a capnograph.
3. End-tidal CO<sub>2</sub> detectors that include a waveform graphical display (capnograph) are the most reliable for verification of tracheal tube position during cardiac arrest. Studies of waveform capnography to verify tracheal tube position in victims of cardiac arrest demonstrate 100% sensitivity and 100% specificity in identifying correct tracheal tube placement.

Waveform capnography is the most sensitive and specific way to confirm and continuously monitor the position of a tracheal tube in victims of cardiac arrest and should supplement clinical assessment (auscultation and visualisation of tube through cords). Waveform capnography will not discriminate between tracheal and bronchial placement of the tube - careful auscultation is essential. Existing portable monitors make capnographic initial confirmation and continuous monitoring of tracheal tube position feasible in almost all settings, including out-of-hospital, emergency department, and in-hospital locations where tracheal intubation is performed. Furthermore, waveform capnography may be a sensitive indicator of ROSC. Such waveform analysis may prove useful in PEA cardiac arrests.

In the absence of a waveform capnograph it may be preferable to use a supraglottic airway device when advanced airway management is indicated.

## Potential problems during tracheal intubation

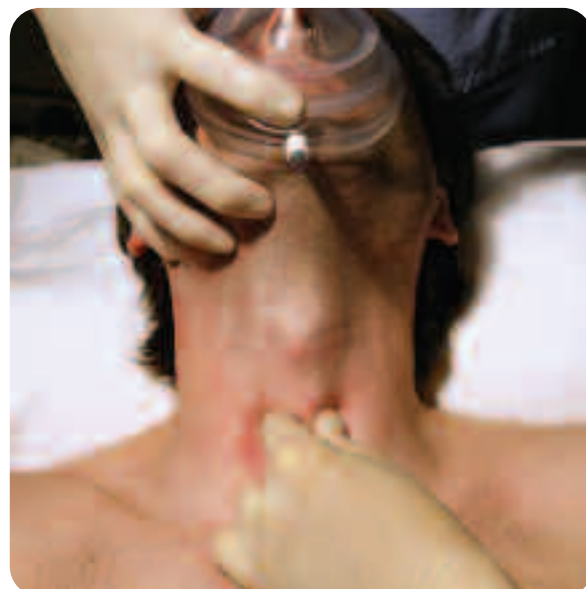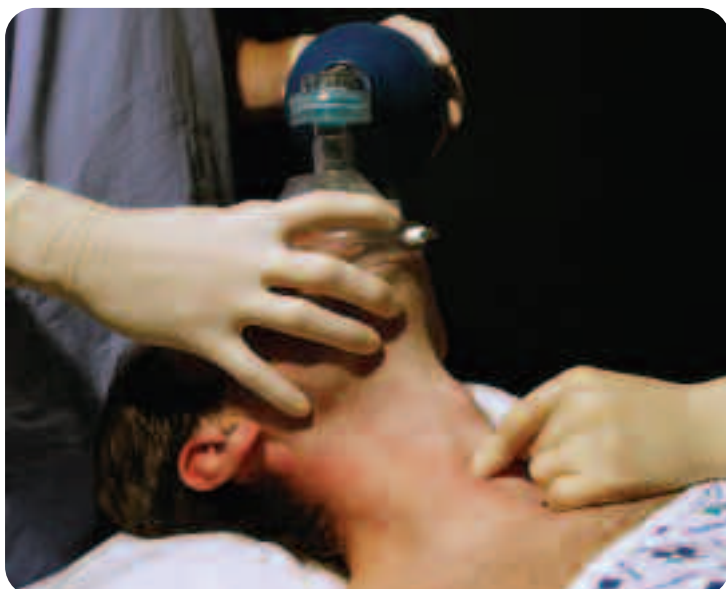Anatomical and pathological variations that may make intubation difficult or impossible include receding lower jaw, short neck, poor movement at the atlanto-axial joint,

prominent incisors, narrow mouth, stiff neck and trismus. If the vocal cords cannot be seen, do not make any attempts to insert the tube blindly. Often a gum-elastic bougie can be inserted through the glottis more easily than a tracheal tube and once in place the tube may be placed over the bougie and guided (rail-roaded) into the trachea. The intubating stylet may also be used to stiffen and pre-form the curvature of the tube or to guide it into the larynx. Problems during intubation may be caused by:

- Facial burns and trauma - it may be impossible to use BLS techniques or intubate patients with severe facial trauma or thermal injury to the upper airway. In such cases it may be necessary to establish a surgical airway, e.g. cricothyroidotomy (see below).
- Upper airway pathology e.g. tumours, infection, swelling from anaphylaxis, etc.
- Insecure/loose teeth or dental prosthesis - these may be damaged or loosened if undue pressure is placed on them. Good intubation technique should reduce this risk.
- Gastric regurgitation - always have a functioning suction device and wide-bore suction to hand. Cricoid pressure may prevent passive regurgitation and pulmonary aspiration.
- Clenching of teeth - in the early stages of resuscitation good CPR may prevent the profound level of unconsciousness required for tracheal intubation. In this case, use basic airway and ventilation techniques.
- Oesophageal intubation - this should not go unrecognised if the recommended protocols are followed, particularly if tracheal tube placement is confirmed with an oesophageal detector device and/or capnometry and capnography. If in doubt, take the tube out and re-oxygenate the lungs using a bag-mask.
- Possible cervical spine injury - suspect this in all patients who have a history of major blunt trauma. Use manual inline stabilisation (MILS) of the head and neck and ensure an experienced operator undertakes the intubation.

## Cricoid pressure

In non-arrest patients cricoid pressure may offer some measure of protection to the airway from aspiration but it may also impede ventilation or interfere with tracheal intubation. The role of cricoid pressure during cardiac arrest has not been studied. Application of cricoid pressure during bag-mask ventilation reduces gastric inflation. Studies in anaesthetised patients, however, show that cricoid pressure impairs ventilation in many patients, increases peak inspiratory pressures and causes



**Figure 7.16 Cricoid pressure**

complete obstruction in up to 50% of patients depending on the amount of cricoid pressure (in the range of recommended effective pressure) that is applied. Do not use cricoid pressure routinely in cardiac arrest. If cricoid pressure is used during cardiac arrest, adjust, relax or release the pressure if it impedes ventilation or tracheal tube placement.

The cricoid cartilage is immediately below the thyroid cartilage, where it forms a complete ring at the upper end of the trachea. A pressure of 30 N (3 kg) is applied anteroposteriorly, forcing the cricoid ring backwards, which compresses the oesophagus against the vertebral column (Figure 7.16). Do not apply cricoid pressure if there is active vomiting: it could cause oesophageal rupture.

## Aids to intubation

### Alternative laryngoscope blade

The Macintosh blade is a good general-purpose blade and a size 3 blade is suitable for most adults. Occasionally, a longer, size 4 blade is better for very large, long-necked patients. The McCoy levering laryngoscope has a hinged tip, and will often improve the view at laryngoscopy. A variety of new videolaryngoscopes are also now available but these are expensive and unlikely to be available in most cardiac arrest settings. A new disposable light assisted laryngoscope (Airtraq) which permits direct visualisation of the larynx via a viewing screen may prove more useful in cardiac arrest settings but, in this context, has been studied only in manikins.

### Introducers

If visualisation is difficult, a gum-elastic bougie may be helpful to guide the tracheal tube into the larynx. It is best inserted into the larynx separately - the tube is then passed over it into the trachea. When correctly placed,

free passage of the bougie is stopped by the smaller airways of the bronchial tree; a bougie placed accidentally in the oesophagus can be inserted completely, without obvious resistance. Ultimately, when ventilation and intubation are impossible and alternatives, e.g. a supraglottic airway device, are not effective, it will be necessary to perform a cricothyroidotomy (see below).

Whilst descriptions of the advanced airway techniques above have been included, these descriptions are not intended as a substitute for practice on manikins, or on anaesthetised patients under the direction of an anaesthetist. Tracheal intubation during cardiac arrest should be attempted only by those undertaking this procedure regularly.

## Suction

Use a wide-bore rigid suction end (Yankauer) to remove liquid (blood, saliva and gastric contents) from the upper airway. This is done best under direct vision during intubation but must not delay achieving a definitive airway. Apply suction to the trachea as briefly as possible and ventilate the lungs with 100% oxygen before and after the procedure. Use fine-bore suction catheters for tracheal suction and pass them directly down the tracheal tube.

## Cricothyroidotomy

Occasionally it will be impossible to ventilate an apnoeic patient with a bag-mask, or to pass a tracheal tube or other airway device. This may occur in patients with extensive facial trauma or laryngeal obstruction caused by oedema, e.g. anaphylaxis, or foreign material. In these circumstances, it will be necessary to create a surgical airway below the level of the obstruction. A tracheostomy is contraindicated in an emergency because it is time consuming, hazardous and requires considerable surgical skill and equipment. Substantial bleeding can occur.

Surgical cricothyroidotomy provides a definitive airway that can be used to ventilate the patient's lungs until semi-elective intubation or tracheostomy is performed. Needle cricothyroidotomy is a much more temporary procedure providing only short-term oxygenation. It requires a wide-bore, non-kinking cannula, a high-pressure oxygen source and may cause serious barotrauma. It is also prone to failure because of kinking of the cannula, and is unsuitable for patient transfer.

### **Surgical cricothyroidotomy**

Unlike needle cricothyroidotomy, the surgical technique will result in an airway that is protected by a cuffed tube. Higher airway pressures can be generated and tracheal suction is possible. Surgical cricothyroidotomy enables ventilation of the lungs despite complete airway obstruction at, or above, the glottis.

#### **Procedure for surgical cricothyroidotomy**

- Place the patient supine with the head extended if possible.
- Identify the cricothyroid membrane as the recess just above the cricoid cartilage and below the thyroid cartilage.
- Incise the skin over the membrane and extend the incision through the cricothyroid membrane. Make a vertical incision in the skin and a horizontal one into the cricothyroid membrane; this avoids the superiorly positioned cricothyroid artery.
- Use the reversed handle of a scalpel or tissue expanding forceps to open up the incision in the cricothyroid membrane.
- Insert a suitably sized tracheal tube into the trachea and inflate the cuff. Do not insert the tube too far into the trachea: the carina is not far from here.
- Ventilate the lungs with a standard self-inflating bag attached to high-flow oxygen. Exhalation occurs directly through the tracheal tube and tracheal suction is also now possible.
- Confirm correct tube placement by auscultation and capnography.

### **Key learning points**

- When undertaken by someone with appropriate skills and experience, tracheal intubation is an effective airway management technique during cardiopulmonary resuscitation.
- In unskilled hands, prolonged interruptions of chest compressions, and the high risk of failure and other complications (e.g. unrecognised oesophageal intubation) make tracheal intubation attempts potentially harmful.

## Section 4. Basic mechanical ventilation

### Learning outcomes

To understand:

- ▶ **The role of automatic ventilators in the peri-arrest period**

There are very few studies that address specific aspects of ventilation during advanced life support. There are some data indicating that the ventilation rates delivered by healthcare personnel during cardiac arrest are excessive. Various small portable automatic ventilators may be used during resuscitation. They are usually gas powered. If an oxygen cylinder is used, both to supply the patient with oxygen and to power the ventilator, the contents may be used up rapidly. Most automatic resuscitators provide a constant flow of gas to the patient during inspiration; the volume delivered is dependent on the inspiratory time (a longer time provides a greater tidal volume). Because pressure in the airway rises during inspiration, these devices are often pressure-limited to protect the lungs against barotrauma. Expiration occurs passively into the atmosphere.

Set an automatic resuscitator initially to deliver a tidal volume of 6 - 7 ml kg<sup>-1</sup> at 10 breaths min<sup>-1</sup>. Some ventilators have co-ordinated markings on the controls to facilitate easy and rapid adjustment for patients of different sizes, and others are capable of sophisticated variation in respiratory pattern. In the presence of a spontaneous circulation, the correct setting will be determined by checking the patient's arterial blood gas values. If a tracheal tube or supraglottic airway has not been inserted, do not attempt chest compressions during the inspiratory phase. Once a tracheal tube has been inserted it is unnecessary to interrupt chest compressions during inspiration. If a supraglottic airway is inserted it may be necessary to synchronise chest compressions with the ventilator if an excessive leak is occurring.

Automatic resuscitators provide many advantages over alternative methods of ventilation.

- In unintubated patients, the rescuer has both hands free for mask and airway alignment.
- Cricoid pressure can be applied with one hand while the other seals the mask on the face.
- In intubated patients they free the rescuer for other tasks.
- Once set, they provide a constant tidal volume, respiratory rate and minute ventilation; thus, they may help to avoid excessive ventilation.

Certain professional first responders (e.g. police, fire, and sports rescue personnel) may use simple automatic resuscitators provided that they have been trained adequately.

### Passive oxygen delivery

In the presence of a patent airway, chest compressions alone may result in some ventilation of the lungs. Oxygen can be delivered passively, either via an adapted tracheal tube or with the combination of an oropharyngeal airway and standard oxygen mask with non-rebreather reservoir. There is insufficient evidence to support or refute the use of passive oxygen delivery during CPR to improve outcome when compared with oxygen delivery by positive pressure ventilation and until further data are available, passive oxygen delivery without ventilation is not currently recommended for routine use during CPR.

### Key learning points

- Automatic resuscitators may be a useful adjunct during cardiopulmonary resuscitation, although there are limited data on their use. Their safe use requires appropriate training.

### Further reading

Deakin CD, Morrison LJ, Morley PT, et al. 2010 International Consensus on Cardiopulmonary Resuscitation and Emergency Cardiovascular Care Science with Treatment Recommendations. Part 8: Advanced Life Support. Resuscitation 2010;81:e93-e169.

Deakin CD, Nolan JP, Soar J, et al. European Resuscitation Council Guidelines for Resuscitation 2010. Section 4. Adult Advanced Life Support. Resuscitation 2010;81:1305-52.

Nolan JP, Soar J. Airway techniques and ventilation strategies. Curr Opin Crit Care 2008;14:279-86.

Wang HE, Simeone SJ, Weaver MD, Callaway CW. Interruptions in cardiopulmonary resuscitation from paramedic endotracheal intubation. Ann Emerg Med 2009;54:645-52.